

Skeletal System

The Skeleton of a horse is very important. It provides body structure, protection of muscles and all the organs, and support of the horse's weight. Joints acts to help the horse move fluidly when walking in a field or being ridden or jumped in a ring. Bones also store essential minerals. There are 205 bones in a horse's skeleton and they can be divided into two sections; the trunk and the limbs. Bone to bone attachments are known as ligaments and bone to muscle attachments are known as tendons. This is how the skeleton is held together

Trunk:

The trunk of the animal includes the skull, spine, ribs and the breast bone.

Key words:

Cranial Bones- encapsulates the brain, provides protection

Facial bones- defines face, forms nasal passage

Maxilla- forms eye socket, adds facial form

Mandible- lower hinged jaw

Cervical Vertebrae- There are 7 vertebrae that make the neck

Thoracic Vertebrae- forms the back, 18 vertebrae

Lumbar- there are 6 vertebrae, forms the loin

Sacral- forms the croup, 5

Coccygeal- It forms the tail, usually with 18 vertebrae

Limbs:

Scapula- shoulder blade

Humerus- "arm" of the horse

Radius- long bone of forearm

Ulna- smaller fused bone, attached to the radius

Carpus- knee composed of 8 carpal bones

Metacarpals – 3 bones, two are splint bones and one is the cannon bone, extends down leg

Fetlock- joint between the cannon bone and bones with in the hoof

Femur- back legs, thigh bone

Patella- "knee"

Tibia- main bone of leg, large long bone

Fibula- smaller bone fused to the tibia

Tarsus- Hock, consists of 7 bones

Long pastern- first phalanx

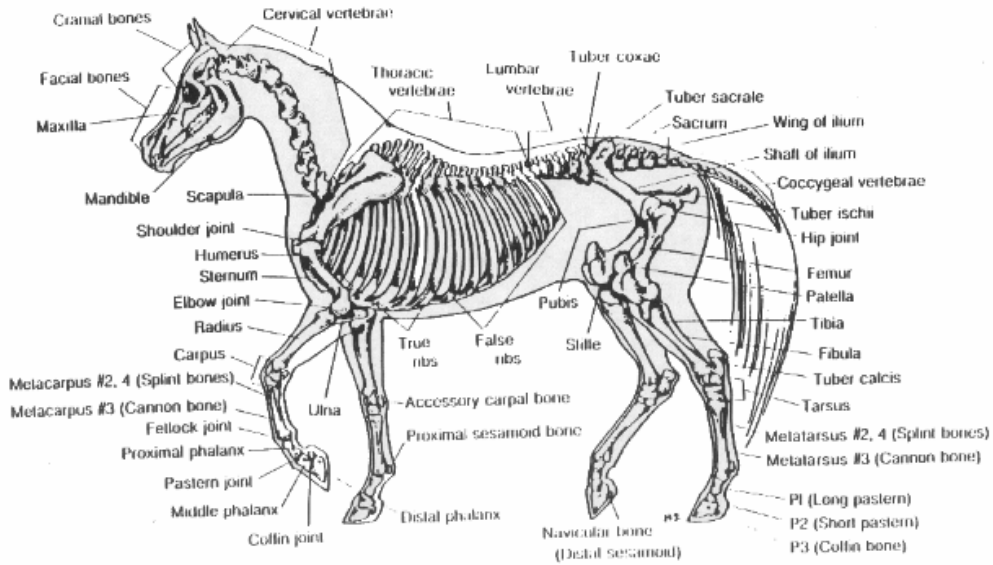
Short pastern- second phalanx

Coffin bone- 3rd phalanx

Navicular- A small bone behind the coffin bone known as the distal sesamoid.



SKELETON OF THE HORSE



International Arabian Horse Association, P.O. Box 33696, Denver, CO 80233-0696